



Case Report

ECG Diagnosis Bidirectional Ventricular Tachycardia

Rajeev Bhardwaj*, Saurav Mittal and Taniya Pruthi

Department of Cardiology, MM Institute of Medical Sciences and Research, Mullana, Ambala 133207, India

Received: 24 January, 2025
Accepted: 07 February, 2025
Published: 08 February, 2025

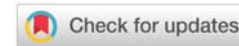
*Corresponding author: Dr. Rajeev Bhardwaj, Professor & Head, Cardiology, MMIMSR, Mullana, Ambala 133207, India, E-mail: rajeevbhardwaj_dr@yahoo.com

ORCID: <https://orcid.org/0000-0002-7650-8607>

Keywords: Ventricular Tachycardia (VT); Bidirectional; Digitalis

Copyright License: © 2025 Bhardwaj R, et al. This is an open-access article distributed under the terms of the Creative Commons Attribution License, which permits unrestricted use, distribution, and reproduction in any medium, provided the original author and source are credited.

<https://www.organscigroup.com>



Abstract

Bidirectional Ventricular Tachycardia (BVT) is a rare type of Ventricular Tachycardia (VT) and shows the beat-to-beat variation of the QRS axis and has high risk of sudden cardiac death. We present one such case, admitted during COVID epidemic.

Introduction

Bidirectional Ventricular Tachycardia (BVT) is a rare form of Ventricular Tachycardia (VT), where QRS complex morphology alternates on a beat-to-beat basis. Due to its rarity, it is not much described in the literature. However, as compared to other arrhythmias, it has limited causes so etiology may be easily found.

Case

A 54-year-old non-diabetic and non-hypertensive female presented with chest pain and breathlessness for two days. There was no history of tobacco, alcohol, or drug abuse. At presentation, her pulse rate was 108/min, blood pressure was 90/60 mmHg. The Electrocardiogram (ECG) report (Figure 1) showed wide QRS tachycardia, regular, rate 107/min., with a beat-to-beat variation of the QRS axis, with evidence of AV dissociation. The QRS duration was about 120 ms. There was ST elevation in lead aVR. Echocardiography showed mild global hypokinesia, with an ejection fraction of 45%. An RT-PCR test for COVID-19 was negative. Electrolytes were within normal limits. She was subjected to coronary angiography, which showed normal coronaries. Tachycardia was unresponsive

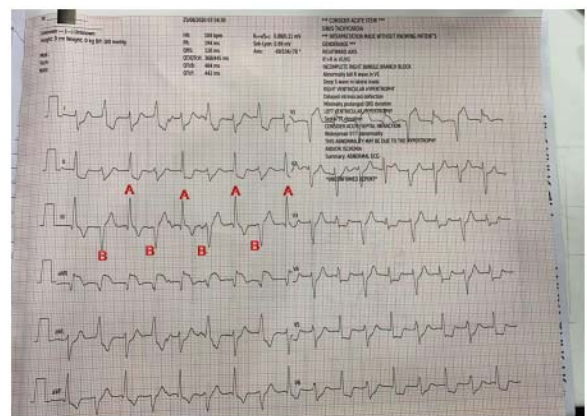


Figure 1: ECG showing bidirectional VT. Two morphologies of QRS complexes, namely A and B with A to A interval 53.5 beats/min and B to B interval of 53.5 beats / min, making tachycardia rate 107/min. Relationship between A to B and B to A is constant, making it regular tachycardia.

to intravenous lignocaine, Esmolol, amiodarone, Flecainide, and three attempts of DC cardioversion of 200 J. Because tachycardia was incessant, and the patient was in hypotension, she was sedated, intubated, ventilated and continued on amiodarone infusion. Two more attempts of DC cardioversion



were unsuccessful. The patient was on inotropes infusion but continued to deteriorate and died after three days. She was planned for a cardiac MRI and PET scan but could not be stabilized for the same.

ECG suggested Bidirectional Ventricular Tachycardia (BVT).

Discussion

BVT is usually regular and shows a beat-to-beat alteration of the QRS axis varying between -20 to -30 degrees and $+110$. Although the most characteristic ECG pattern of BVT is the right bundle branch block with an alternating QRS axis [1], other patterns such as alternating right bundle branch block and left bundle branch block, or alternating QRS axis with a narrow QRS, have also been observed [2]. The mechanism of bidirectional VT is believed to be the result of two different sites in the distal His Purkinje system or ventricle where Delayed after Depolarization (DAD) develops at different heart rate thresholds. This results in a "Ping-Pong" mechanism that causes reciprocating bigeminy between these two ventricular foci.

The causes of BVT include Digitalis toxicity, fulminant myocarditis, hypokalemic periodic paralysis, left ventricular noncompaction, cardiac sarcoidosis [3], aconite poisoning, Andersen-Tawil syndrome, and ventricular tachycardia catecholaminergic polymorphic syndrome.

Due to the high risk of Ventricular Fibrillation (VF) and sudden death, symptomatic BVT has an unfavorable prognosis

[4]. The patient's prognosis largely improves if cardioversion is achieved, i.e., if the heart rhythm can be normalized. For a better outcome, recurrence has to be avoided. In the short term, this can be attained by the administration of an antidote like digoxin-specific antibody fragments, if it is due to digitalis.

Conclusion

BVT is a rare form of VT, the common cause of which is digitalis toxicity. It has a poor prognosis due to its tendency to degenerate into VF and cause sudden death. It may be difficult to treat.

References

1. Leenhardt A, Lucet V, Denjoy I, Grau F, Ngoc DD, Coumel P. Catecholaminergic polymorphic ventricular tachycardia in children. A 7-year follow-up of 21 patients. *Circulation*. 1995;91(5):1512-9. Available from: <https://doi.org/10.1161/01.cir.91.5.1512>
2. Rothfeld EL. Bidirectional tachycardia with normal QRS duration. *Am Heart J*. 1976;92:231-23. Available from: [https://doi.org/10.1016/s0002-8703\(76\)80259-1](https://doi.org/10.1016/s0002-8703(76)80259-1)
3. Durocher D, El-Hajjaji I, Gilani SO, Leong-Sit P, Davey RA, De SK. Bidirectional ventricular tachycardia in a patient with fulminant myocarditis secondary to cardiac sarcoidosis mimicking giant cell myocarditis. *CJC Open*. 2021;3(12):1509-1512. Available from: <https://doi.org/10.1016/j.cjco.2021.07.007>
4. Menduñia MJ, Candel JM, Alaminos P, Gómez FJ, Vilchez J. Bidirectional ventricular tachycardia due to digitalis poisoning. *Rev Esp Cardiol*. 2005; 58(8):991-993. Available from: <https://pubmed.ncbi.nlm.nih.gov/16053836/>

Discover a bigger Impact and Visibility of your article publication with Peertechz Publications

Highlights

- ❖ Signatory publisher of ORCID
- ❖ Signatory Publisher of DORA (San Francisco Declaration on Research Assessment)
- ❖ Articles archived in worlds' renowned service providers such as Portico, CNKI, AGRIS, TDNet, Base (Bielefeld University Library), CrossRef, Scilit, J-Gate etc.
- ❖ Journals indexed in ICMJE, SHERPA/ROMEO, Google Scholar etc.
- ❖ OAI-PMH (Open Archives Initiative Protocol for Metadata Harvesting)
- ❖ Dedicated Editorial Board for every journal
- ❖ Accurate and rapid peer-review process
- ❖ Increased citations of published articles through promotions
- ❖ Reduced timeline for article publication

Submit your articles and experience a new surge in publication services

<https://www.peertechzpublications.org/submission>

Peertechz journals wishes everlasting success in your every endeavours.